



PATIENT

Simoney Scott

SPECIES

Feline

BREED

DSH

SEX

Female Spayed

AGE

15 years

WEIGHT

6.68lbs

INTERPRETED BY

Maggie Machen
Lamy, DVM, DACVIM
(Cardiology)

HOSPITAL NAME

Timonium Animal
Hospital

REFERRING VET

Dr. McMichael

INVOICE

21326

DATE

10/1/21

PRESENTING CLINICAL SIGNS

History: Concern for stroke/clot vs primary neurologic event 9/21. Presented to ER with ataxia and no menace. circling to the L.

-Pertinent abnormal PE/Chem/CBC/UA Results: T4: 2.3, Chemistry panel normal (Glu: 208- suspect stress) , CBC: mild leukocytosis (Neutrophils:12.13K) , BNP: abnormal

-Current medications: Clopidogrel 75mg tab: 1/4 tab PO q24h, Amlodipine 2.5mg tab: 1/4 tab PO q24h, Gabapentin 25mg PO for stress/anxiety PRN.

-Blood pressure: BP: 172/147mmHg.

-Sedation used: Gabapentin and Butorphanol administered prior to scan.

-STAT: Not requested.

ECHOCARDIOGRAM FINDINGS

2D, m-mode, color flow and doppler imaging is available. The left ventricular wall is largely normal in dimension with mild focal septal thickening. There is a diffusely hyperechoic endocardium consistent with fibrosis. The papillary muscles are mildly remodeled and hyperechoic. The left atrium is normal in size. The right atrium is normal in size. The right ventricle appears normal. The mitral valve is normal in structure and mobility. Trace MR and TR are noted. Blood flow through both the LVOT and RVOT is normal in velocity. No pleural or pericardial effusion seen. No obvious cardiac tumors.

CARDIAC CHART

FELINE CARDIAC PARAMETERS	BODY WEIGHT (kg)	HR (BPM)	IVSd (cm) (Moise, Pipers)	LVIDd (cm) (Moise, Pipers)	LVWd (cm) (Moise, Pipers)	FS (%)	EF (%)
NORMAL PARAMETER	-----	150-240	3.5-0.55	<2 (mean 1.5)	3.5-0.55	35-67	80-100
PATIENT	3.0	266	0.56	1.16	0.47	40	76
FELINE CARDIAC PARAMETERS	LA/AO (Boon)	LA/AO HEART BASE (Swe) (Abbott)	LA 2D short axis Base view (cm) (Abbott)		LVOT VEL (m/s)	RVOT VEL (m/s)	E max (m/s)
NORMAL	<1.5	<1.3	<1.2		<1.6	<1.3	<0.9
PATIENT	NM	1.3	1.2		0.64	1.1	NM

Adapted from June Boon, Veterinary Echocardiography,1998
Abbott J & MacLean H JVIM 2006;20: 111-119, Moise et al. Am J Vet Res 47:1476, 1986. Pipers et al. Am J Vet Res 40:882, 1979.

INTERPRETATION OF THE FINDINGS & FURTHER RECOMMENDATIONS

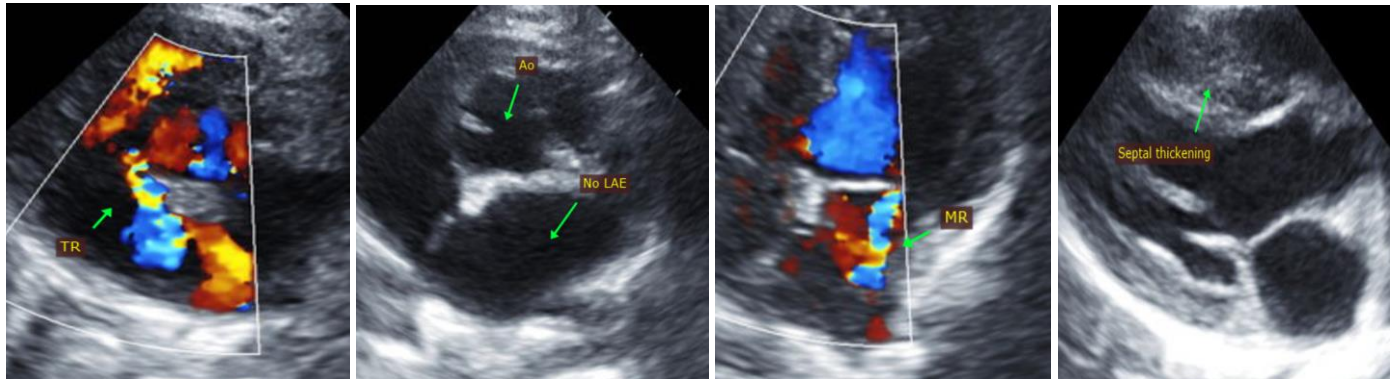
Overtly normal geriatric cardiac structure and function. The septum is borderline in thickness which may be a normal variant or may be indicative of early hypertrophic disease. Trace MR and TR are hemodynamically insignificant. There is no evidence of elevated left atrial pressure. There is increased remodeling and fibrosis of the left ventricular wall, which should be monitored as well. Serial echocardiography will be necessary to determine progression.

Given these findings, no cardiac medications are indicated. A normal left atrial size would make a cardiogenic thrombus highly unlikely. This does not rule out non-cardiac thrombi (typically due to neoplasia or vascular event) which should also be considered pending further evaluation. Further neurologic evaluation may also be useful.

Anesthetic risk is considered mild. With this degree of remodeling and diastolic stiffening, there is an elevated risk for fluid overload in this patient and judicious IV fluid use is recommended. Heart rate stimulating drugs such as atropine, glycopyrrolate or ketamine should be avoided unless medically necessary.

Recommend recheck echocardiogram in 6-12 months to assess for progression, sooner if a murmur or gallop rhythm develops in the interim.

IMAGES



The information and recommendations provided are based on the images presented by the referring veterinarian. No evaluation can be communicated regarding pathology that was not visible in the image/video clips provided.

Thank you for this referral. This report was generated using transcription software, and minor dictation errors may be present. If the clinical or image interpretation does not parallel your findings or if I can be of any further assistance, please contact me.

Maggie Machen Lamy, DVM
Diplomate of the American College of Veterinary Internal Medicine (Cardiology)
Email: info@sonopath.com